

RESEARCH

Open Access

Bilateral asymmetric tonic seizure in insulo-opercular epilepsy: an anatomo-electro-clinical study



Xiangshu Hu^{1*} , Kaihui Li¹, Xiao Wang¹, Ping Yang², Qinghua Tan¹, Danfang Li¹, Xiaobo Wang¹, Fang Zeng¹, Yang Jin¹, Lingxia Fei¹, Hua Li¹, Junxi Chen¹ and Qiang Guo¹

Abstract

Background: Insulo-opercular seizures are highly heterogeneous in seizure semiology and electrical features. Bilateral asymmetric limb posturing, as a classical pattern of supplementary sensorimotor area (SMA) seizure, also occurs in insulo-opercular epilepsy. This study was aimed to study the anatomo-electro-clinical correlations in bilateral asymmetric tonic seizures (BATS), in order to advance the understanding of insulo-opercular epilepsy.

Methods: Eight patients with insulo-opercular epilepsy as confirmed by stereoelectroencephalography (SEEG) and manifesting BATS as the major ictal motor sign, in Guangdong Sanjiu Brain Hospital Epilepsy Center from 2014 to 2018, were employed in this study. The BATS of the patients were evaluated, and the semiologic features and concomitant intracerebral EEG changes were quantified. Then the variables were examined with Cluster Analysis, and the semiologic features were correlated with anatomic localization using the Kendall correlation test.

Results: Of the 8 patients, the most frequent initial motor sign was bilateral asymmetric tonic posturing (62.5%). Facial tonic-clonic sign also had a high prevalence in the evolution of seizures (87.5%). The results of Cluster Analysis showed that the semiologic features were subdivided into two main groups, one group comprising exclusively BATS and the other including signs of focal tonic seizure, aura, focal limb tonic-clonic seizure (TCS), facial TCS, hypermotor behavior, eye movement, autonomic changes and generalized TCS. The BATS was strongly associated with the posterior long gyrus (PLG) of insula ($t = 0.732$) and parietal operculum ($t = 1.000$); the hypermotor behaviors were associated with the anterior long gyrus (ALG) ($t = 0.770$); and the autonomic changes were associated with the anterior limiting sulcus (ALS) ($t = 0.734$) and middle short gyrus (MSG) ($t = 0.700$).

Conclusions: The seizure semiology of insulo-opercular epilepsy is characterized, in temporal order, by BATS, with or without simultaneous hypermotor behaviors, and frequently ends up with facial tonic-clonic signs, which is different from that of the SMA seizure. The early spread network involving the posterior insular lobe and parietal operculum may contribute to this pattern of manifestation.

Keywords: Insulo-opercular epilepsy, Semiology, Bilateral asymmetric tonic seizures, Stereoelectroencephalography

* Correspondence: hxs75@126.com

¹Epilepsy Center, Guangdong Sanjiu Brain Hospital, No 578, Shatai South Road, Baiyun District, Guangzhou 510510, Guangdong, China
Full list of author information is available at the end of the article



© The Author(s). 2020 **Open Access** This article is licensed under a Creative Commons Attribution 4.0 International License, which permits use, sharing, adaptation, distribution and reproduction in any medium or format, as long as you give appropriate credit to the original author(s) and the source, provide a link to the Creative Commons licence, and indicate if changes were made. The images or other third party material in this article are included in the article's Creative Commons licence, unless indicated otherwise in a credit line to the material. If material is not included in the article's Creative Commons licence and your intended use is not permitted by statutory regulation or exceeds the permitted use, you will need to obtain permission directly from the copyright holder. To view a copy of this licence, visit <http://creativecommons.org/licenses/by/4.0/>.

Background

Bilateral asymmetric tonic seizures (BATS) are characterized by sustained tonic posturing of trunk and limbs that is bilateral but asymmetric. Electrical stimulation of the supplementary motor area (SMA) can elicit this characteristic posturing, which has been accepted by The International League Against Epilepsy (ILAE) as one of the distinctive ictal semiological characteristics of SMA seizures [1]. BATS is also one of the seizure types in mesial frontal lobe epilepsy manifesting “postural, focal tonic with vocalization, speech arrest, and fencing postures”. Ictal BATS could be an essential clue to localizing seizure in SMA [2]. However, there have been a few cases of BATS reporting other origins such as the posterior cingulate cortex, the parietal cortex and the insular-operculum [3–5].

Some studies indicated that insular epilepsy is a great mimicker. Intracranial electroencephalogram studies have demonstrated that besides the “perisylvian” clinical pattern, the insular seizures could also manifest with “temporal-like” symptoms, “frontal-like” symptoms, and even with epileptic spasms. The “frontal-like” symptoms, which are hyperkinetic behaviors or tonic motor signs, are the most misleading signs for seizure localization [6]. In a recent study of pure insular-onset epilepsy by Peltola et al. [7], BATS was seen in three of the 11 patients (27%). Stereoelectroencephalography (SEEG) evaluation confirmed seizure onset zones in the anterior long gyrus (ALG) or both anterior long gyrus and posterior long gyrus (PLG). Another study of patients with insulo-opercular epilepsy based on SEEG identified two cases with BATS among 22 patients [8], with seizure onset zones localized in the middle short gyrus (MSG), posterior short gyrus (PSG), opercular cortex and MSG, and triangular part of inferior frontal gyrus (IFG).

In a recent study of five insular lobe epilepsy patients, non-linear analysis of 3 patients with frontal semiology showed strong ictal coupling with the mesial frontal as well as cingulate regions, including the medial orbitofrontal cortex, pre-SMA/SMA, and the anterior to posterior cingulate. One patient with seizure onset zone of ALG and PLG, manifesting symmetric axial dominant tonic posture, showed bidirectional functional coupling between the PLG and posterior cingulate gyrus. Otherwise, the patient with seizure onset zone of MSG and PSG had focal somatosensory aura and focal tonic seizure, due to ictal propagation to mesial frontal (SMA/pre-SMA) and cingulate regions [9].

To date, the insulo-opercular epilepsy remains challenging due to its complex semiology and localization. Although there have been studies on selected types of insulo-opercular epilepsy, a comprehensive overview of insulo-opercular seizures manifesting BATS is still lacking. In this study, we employed patients with seizure

onset in the insular and/or opercular cortex identified by SEEG to investigate (1) if the insulo-opercular epilepsy patients with BATS can be uniquely characterized in terms of semiology; and (2) if BATS originating from insulo-opercular areas are associated with an early spread network.

Methods

Patients

During January 2014 and December 2018, there were 38 insulo-opercular epilepsy cases in the Epilepsy Center of Guangdong Sanjiu Brain Hospital (GuangZhou, China). Of them, eight patients both had defined epileptogenic zone within the insular-operculum as identified by SEEG and manifested with bilateral asymmetric tonic posturing as the major ictal motor sign, so they were employed in this study. All patients were followed up for at least 6 months. Patients without definite SMA hypometabolism in PET images were excluded from this study [10].

The comprehensive noninvasive presurgical evaluation included a detailed clinical history review and scalp video-electroencephalography (VEEG, Nihon Kohden) recording, in order to analyze habitual seizures and interictal discharges. MRI (1.5-Tesla, Philips Medical Systems, Netherlands), PET-CT (18FDG, GE, USA), neuropsychological assessment, and functional imaging were conducted when needed. SEEG was recorded using intracerebral multiple contact electrodes (manufactured by Huake Hengsheng [Beijing, China] for non-eloquent cortex exploration in patients; Alcis [Besancon, France] for eloquent cortex exploration in patients) placed intracranially according to Talairach’s stereotactic method. All patients gave written informed consent before implantation. Strategy of electrode implantation in each patient was based on working hypotheses about epileptogenic zone and lesion boundary, aiming to define resection boundary. Eight to 17 (13 in average) electrodes were intracranially implanted in each patient. Three patients were implanted bilaterally. SEEG (128 or 256 channels, Nihon Kohden system, Japan) was performed during a period of 9–19 (14.5 in mean) days to record habitual seizures of the patients, with partial or complete withdrawal of antiepileptic drugs. Electrical cortical stimulation (50 Hz, 0.3 ms, biphasic, bipolar, for 3 to 5 s) was performed after epileptogenic zone localization.

Analysis of anatomical electroclinical features

SEEG data of each patient were analyzed by two neuroelectrophysiologists independently (HXS, WX, TQH or LDF).

Considering the complex manifestation of insular-opercular seizures, the presence or absence of 8 ictal symptoms in selected seizures for each patient was noted: (1) aura, (2) autonomic changes, (3) focal tonic

seizures involving the face, eyelids or limbs, (4) bilateral asymmetric tonic posturing, (5) focal tonic-clonic seizure (TCS) involving face, eyelids or limbs, (6) hypermotor behaviors, (7) eye movement including forced eye stare, deviation, convergence, or versive, and (8) generalized tonic clonic seizure (GTCS). As expected, the electroclinical pattern of included seizures for a given patient exhibited a characteristic of relatively high repeatability. The overall semiology was scored at a scale of 0–2 for each patient based on the reviewing of all seizures during the awake stage and 5 seizures during sleep: 2, major features (constant and early sign presence in each seizure); 1, minor features (signs occur infrequently or are present after initial sign); and 0, absence of signs [11].

Definition of early spread network when ictal BATS emerges

All included seizures of each patient were reviewed to analyze the involvement of different cortical regions in ictal discharges according to the level of participation during ictal phase. Electrode sampling allowed detection of 16 anatomical cortical structures within the bilateral insular lobes and the operculum and mesial frontal structures [12]: (1) anterior short gyrus (ASG), (2) MSG, (3) PSG, (4) ALG, (5) PLG, (6) apex, (7) anterior limiting sulcus (ALS), (8) superior limiting sulcus, (9) inferior limiting sulcus, (10) triangular part of the inferior frontal gyrus, (11) opercular part of the inferior frontal gyrus, (12) central operculum: including ventral part of precentral gyrus, postcentral gyrus and subcentral gyrus, (13) parietal operculum: an area within the supramarginal gyrus along the posterior ascending rami of lateral fissure, (14) temporal operculum: comprising planum temporale, Heschl's gyrus and planum polare, (15) SMA, and (16) middle part of cingular cortex (MCC) [13].

The time window was set from the onset of electrical activity to the occurrence of bilateral asymmetric tonic posturing, in which to identify the subset of cortical structures underlying the generation of ictal BATS. These structures are known as the “early spread network” according to Chauvel's research [11]. The degree of participation of each structure was scored based on both the timing of the emergence of ictal discharge in that cortex and the level of change in amplitude, frequency, or rhythmicity compared to the preictal discharge in the same cortex. The score of 2 indicates a structure immediately involved in electrical onset by a low-voltage fast activity (LVFA); score of 0 indicates a structure not involved in seizure activity within the time window; and score of 1 indicates a structure involved later within the time window of BATS, or having concomitant ictal discharge characterized by lower-frequency rhythmic activity [14].

Statistical analysis

Automatic hierarchical cluster analysis was performed to obtain ordered sequences of ictal symptoms or cerebral cortices, based on their co-occurrence frequency. Correlations between ictal symptoms (BATS mainly) and cortices were analyzed and the strength of association calculated by the Kendall correlation test. $P < 0.05$ was considered as statistically significant.

Results

General characteristics

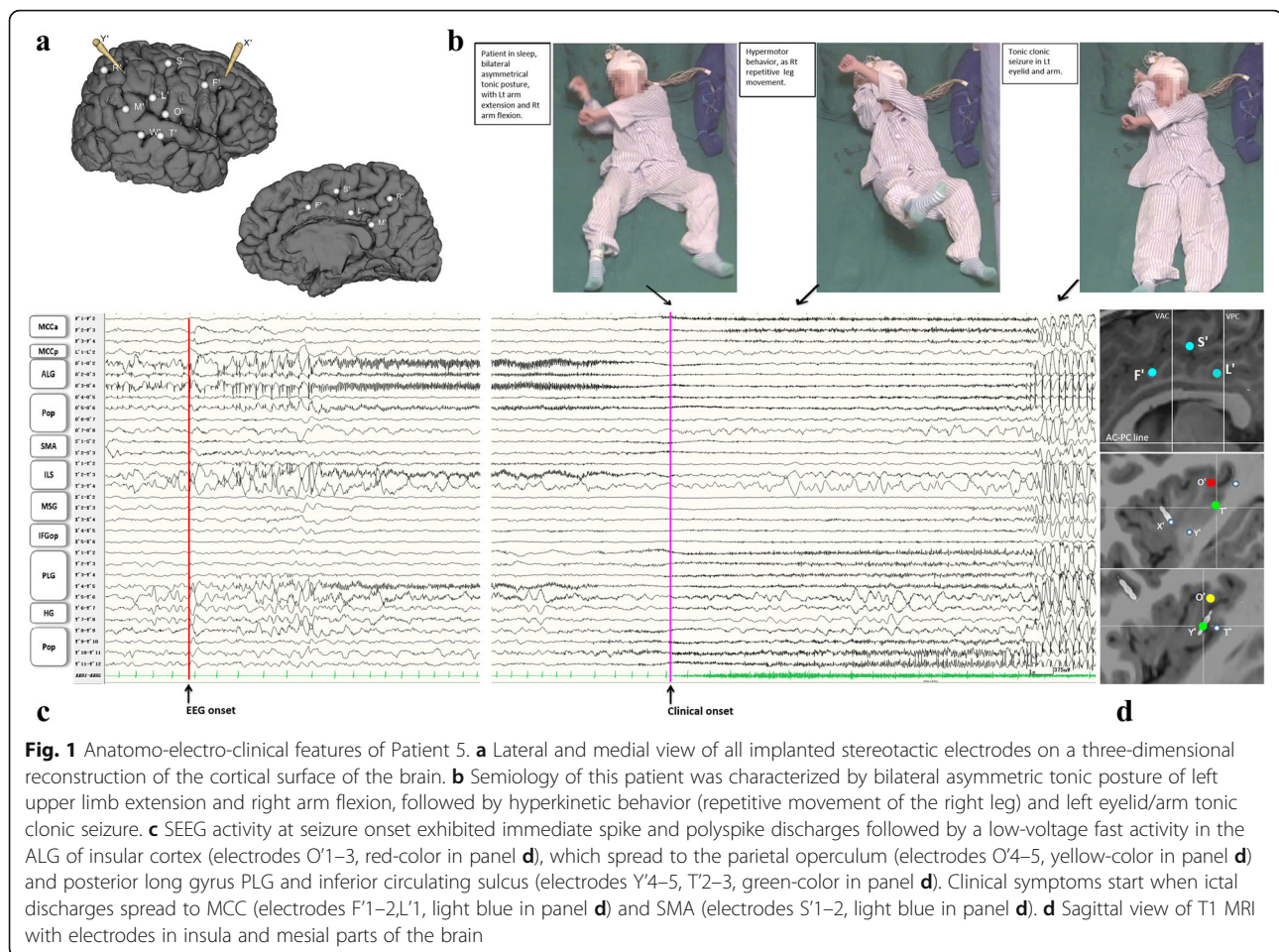
The eight patients were 7 males and 1 female, with average age of 13 ± 7.2 years and mean epilepsy duration of 8.8 ± 6.0 years. Two patients had normal MRI. Seven patients (87.5%) underwent surgical resection after SEEG exploration, and one patient (No. 8) received stereotactic radiofrequency thermocoagulation (RFTC), because of localization of epileptogenic zone in the Broca's area. All patients were followed up for at least 6 months. Six cases reached Engel class I outcome (75%), and the other two had class II and class III outcomes, respectively. Histopathology of the resected specimens ($n = 7$) revealed five patients (71%) having focal dysplasia, one with gliosis, and one with nonspecific changes.

Semiologic features

A total of 60 seizures were analyzed, 20 at awake state and 40 in sleep. Two patients displayed exclusively sleep-related seizures and other two patients had a high percentage of nocturnal seizures as well. The appearance of each ictal symptom and brain regions involved in the early spreading network at the occurrence of BATS were noted for each patient. The bilateral asymmetric tonic posturing occurred in all patients, as initial motor signs in 5 patients (62.5%). Focal tonic sign occurred in 4 (50%) patients, which was the second frequent early motor signs in 3 (37.5%). Other following motor signs included facial TCS with or without focal limb TCS in 7 patients (87.5%), hypermotor behavior in 2 (25%), eye-movement in 4 (50%), GTCS in 1 patient, aura (contralateral somatosensory, or indescribable aura) in 2, and autonomic changes (nausea or hypersalivation) in 2 cases (Table 2).

SEEG findings

A total of 101 SEEG electrodes were implanted in the 8 patients using the stereotactic robot system (ROSA, Medtech, France). Forty-one electrodes (average 5 for each patient) simultaneously covered the insular and opercular cortex. SMA and MCC were explored respectively in seven cases (Table 1). Six patients were detected with seizure onset zone in the insula, of whom three patients showed early spread of ictal discharges to the operculum (representative illustration in Fig. 1), while



the other three having ictal discharges within the insular cortex. Two of eight cases had an opercular onset, one showing early spread to the insula, while the other within the operculum (Table 2).

Cluster analysis and anatomical electroclinical correlations

Clinical semiology and cerebral structures as part of the early spread network as classified with cluster analysis are shown in Fig. 2. Semiology of the patients was divided into two groups, one group including exclusively BATS and the other consisting of other symptoms including focal tonic seizure, aura, focal limb TCS, facial TCS, hypermotor behaviors, eye movement, autonomic changes and GTCS. Lower levels of ictal signs at smaller clusters were most likely present in the same seizure sequence, such as facial TCS and focal limb TCS, hypermotor behaviors and autonomic changes.

Cluster analysis of brain regions showed a cluster comprising the middle part of insular regions, parietal operculum, and MCC, separated from anterior and posterior insular regions, frontal-central operculum, and SMA. In addition, smaller groups of brain structures grouped together at lower cluster levels also showed

strong associations, such as parietal operculum and MCC; ASG, MSG and SMA; and central operculum and superior limiting sulcus.

Kendall correlation test showed that BATS were strongly associated with PLG ($t = 0.732$) and parietal operculum ($t = 1.000$); hypermotor behavior with ALG ($t = 0.770$), and autonomic changes with the ALS ($t = 0.734$) and MSG ($t = 0.7000$). On the other hand, aura, focal limb TCS, focal facial TCS, and GTCS showed a weak association with PLG ($t = 0.630$), PSG ($t = 0.564$), MCC ($t = 0.577$), and central operculum ($t = 0.642$), respectively (Fig. 2).

Discussion

In this study, we found that the insular-opercular epilepsy is characterized by symptoms of BATS, which are sometimes accompanied by hypermotor behaviors and frequently end up with facial TCS. This series of symptoms would be a clear marker of insulo-opercular seizures from SMA ones. Early spreading network of posterior insular lobe and parietal operculum may contribute to this pattern of manifestation.

Table 2 Evolution of semiology and seizure location based on SEEG data

Patient No. (n = 8)	No. of seizures recorded	No. of seizures analyzed (A20,S40)	Seizure duration	BATS duration	Evolution of semiology	Seizure onset and propagation		Stimulation site		Epileptogenic zone
						SIA	SIS	SIA	SIS	
1	A0,S6	S5	77–100 s	9–22 s	Focal tonic (Rt arm occurring in 2 out of 5 seizures [2/5]) → BATS (four limbs 5/5, face 4/5) → EM (cont. Deviation 3/5, ips.deviation 1/5, convergence 1/5) → Focal TCS (Rt arm 1/5, face 5/5) → GTCS (5/5)	Cop → MCC + sls + Fop	Undone	Undone	Undone	Lt-INS + OP
2	A1,S12	A1,S5	5–52 s	5–19 s	Aura (Rt arm numb 3/6) → Autonomic (nausea 1/6) → BATS (4limbs 6/6, face 2/6, ipseyelid 2/6) → Focal TCS (eyelids 4/6)	plg + sls → asg	Undone	Undone	Undone	Lt-INS
3	A3,S12	A3,S5	27–42 s	20–32 s	Autonomic (tachycardia 8/8, hypersalivation 2/8) → Focal dystonia (Rt hand 2/8) → BATS (four limbs 8/8, cont.face+eyelid 5/8) → Hypermotor (shake head 4/8) → Focal TCS (throat 2/8, eyelids 3/8)	msg → asg → alg + plg + als	Undone	Undone	Undone	Lt-INS
4	A16,S46	A5,S5	13–66 s	7–56 s	Aura (undescribable) → BATS (four limbs 10/10, face 3/10) → Focal TCS (Rt arm 8/10)	plg → ils → psg	plg, ils, Pop	Not induced	Not induced	Lt-INS
5	A0,S41	S5	20–23 s	14–20 s	BATS (four limbs 5/5) → Hypermotor (pedaling 3/5) → Focal TCS (Lt arm 5/5, eyelid 5/5)	alg → Pop → plg	Not induced	Pop, HG	Pop, HG	Rt-INS + OP
6	A2,S46	A2,S5	22–69 s	7–29 s	BATS (four limbs 7/7) → EM (forced upward stare 3/7, cont.deviation 1/7) → Focal TCS (Lt arm 4/7, eyelid 3/7)	plg → sls → apex+psg + Pop + TP	Undone	Undone	Undone	Rt-INS + OP
7	A > 50, S > 50	A5,S5	12–35 s	9–20 s	BATS (four limbs 10/10) → Focal tonic (Rt face+eyelid 8/10) → EM (ips.deviation 6/10) → Focal TCS (limbs 6/10, eyelids 10/10)	psg → Cop → plg + ils + msg + Pop + SMA	Undone	Undone	Undone	Lt-INS + OP
8	A10,S7	A5,S5	8–62 s	6–31 s	Focal tonic (pouting 2/10) → BATS (four limbs 10/10, face 6/10) → EM (ips.deviation 2/10, cont. deviation 1/10)	IFGop	Not induced	ds	Not induced	Lt-OP

S/A stimulating induced aura, SIS stimulating induced seizure, A awake, S sleep, Lt left, Rt right, Bil bilateral, cont contralateral, ips ipsilateral, BATS bilateral asymmetric tonic seizure, TCS tonic-clonic seizure, GTCS generalized tonic clonic seizure, EM eye movement, SMA supplementary sensorimotor area, asg anterior short gyrus of insula, msg middle short gyrus of insula, psg posterior short gyrus of insula, alg anterior long gyrus of insula, plg posterior long gyrus of insula, als anterior limiting sulcus, ils inferior limiting sulcus, sfs superior limiting sulcus, OP operculum, Fop frontal operculum (inferior frontal gyrus triangular part and opercular part), IFGop inferior frontal gyrus opercular part, ds diagonal sulcus, Cop central operculum, Pop parietal operculum, Top temporal operculum, MCC middle part of cingular cortex, TP temporal pole, HG Heschl's gyrus

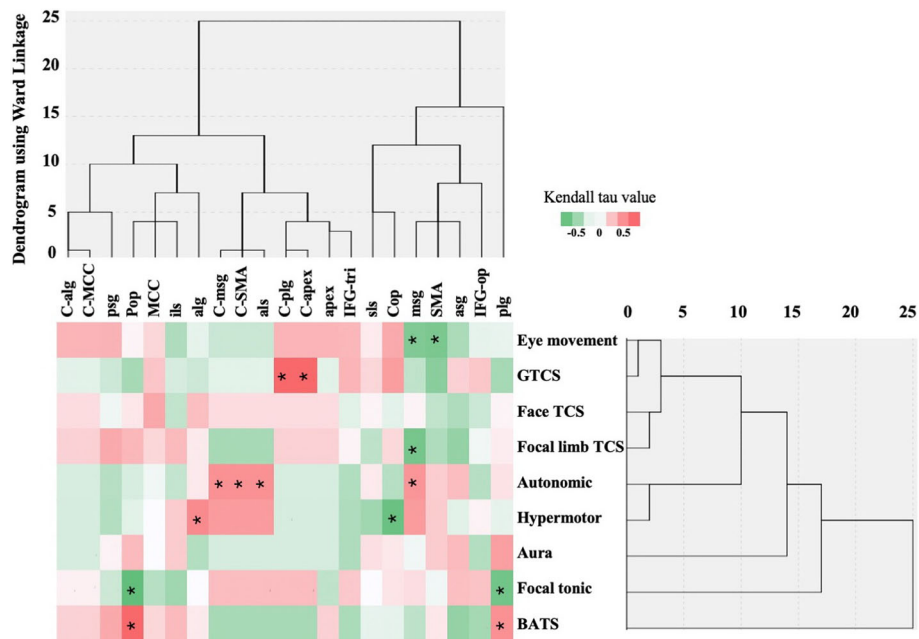


Fig. 2 Correlation matrix between clinical features and cortical structures. Upper: Clustering of cerebral cortical areas. Lower right: Clustering of clinical symptoms. Lower left: Correlation between structures and symptoms (green, negative correlation; red, positive correlation), which shows components of seizure semiology related to different early spread networks in varying degrees. * $P < 0.05$

Seizure semiology

According to previous studies on insular epilepsy, the initial signs of awake seizure of insulo-opercular epilepsy include laryngeal constriction, perioral unpleasant paresthesia, lateralized somatosensory sensations, and/or autonomic symptoms. With progression, dysarthria and/or later motor symptoms occur with or without loss of consciousness. Nocturnal seizures are typically displayed as hypermotor or BATS. Sleep-related BATS in insular epilepsy is as frequent as in SMA epilepsy [2]. In 6 patients with SMA epilepsy in a previous study, BATS occurred 100% in sleep in 3 patients, and 79% in the other three cases. As a principal feature of BATS, tonic posturing was constant and asymmetric in individual patients, whose upper limbs contralateral to the epileptogenic cortex were typically kept in abduction and extension. The posture occurred and remained stable in the first half period of the seizure. However, a certain number of patients with SMA epilepsy could even present with unilateral tonic seizure as reported. In contrast, patients in the extra-SMA group have a higher incidence of bilateral symmetrical tonic limb posturing [5]. In our insulo-opercular group, the posture of bilateral tonic contractions in four limbs as starting motor sign or in the course of seizure evolution, was extension or flexion similarly in both arms or prominent in the contralateral upper limb. Meanwhile, facial tonic seizure along with BATS and the following eyelid TCS (contralateral or ipsilateral to the epileptogenic cortex or bilateral),

occurred more frequently in our group than in SMA group from other studies [2].

Electrographic findings

LVFA is the most common pattern of seizure onset detected by intracranial recordings [15]. Previous findings showed that seizure symptoms are heterogeneous in insulo-opercular epilepsy. Frontal semiology like nocturnal BATS is more general in patients with seizure onset zone in posterior insular cortex, while hypermotor signs, speech changes, and viscerosensor signs are related to seizure onset zone in the anterior insular region. Propagation of insular seizures is typically from inside the insula to extrainsular connections [7]. The contralateral insula engagement could also be very fast in less than 1 s [16]. Here, we found that the posterior insular onset seizures spread both to extrainsular and intransular regions, while opercular onset seizures tend to propagate to extrainsular regions.

Anatomical electroclinical correlations

A recent model based on tract-tracing data and functional studies in macaque monkeys proposes an integrative flow of interoceptive information processing from the dorsal granular insula to the intermediate dysgranular insula and finally to the anterior agranular insula. The very dorsal-caudal part of PLG belongs to granular insula and functions in somatosensory and vestibular processing [17]. Accordingly, somatosensory aura is a clue for

seizure onset zone localization in posterior insula. In fact, most of the sleep-related seizures in this study started with motor symptoms, while aura was hardly noticed. In addition, the somatosensory representation area comprises two-thirds of the insula. Somatosensory symptoms could originate from both the posterior and anterior insula. Thus, the nonpainful sensory symptoms did not lead to an accurate localization [7].

Ictal nausea is a specific viscerovegetative sensation, often associated with temporal lobe epilepsy in the presence of propagation of the ictal discharge to the anterior insular cortex [18, 19]. A fMRI study found that during the evolution of nausea, the anterior insula was persistently activated to cause strong sensation and correlated with MCC [20]. Moreover, stimulation of the insular cortex mainly occurs in the middle part, evoking nausea as one of the major viscerovegetative responses [21]. In our cases, nausea was associated with seizure onset zone in posterior insula, which later spread to the anterior insular cortex (especially MSG and ALS).

Activation of anterior and posterior insula generate different motor symptoms [7]. We observed that in patients with BATS but without hypermotor seizures, the seizure onset zone was located in PLG or the frontal/central operculum; while in the context of BATS with hypermotor seizures, the seizure onset zone moved to rostral part of insula, as ALG or MSG. Cytoarchitectonic observation revealed dysgranular cortex in a large part of insula, particularly around the central insular sulcus. The dysgranular insula in monkeys has been subdivided into 2 separate fields. The dorsal dysgranular field receives a somatotopic representation of innocuous tactile input via its connectivity to the dorsal dysgranular primary somatosensory area, forming distinct patches connected with the posterior parietal cortex (PPC), ventral premotor cortex (PMV), and SMA. The ventral dysgranular insula has extensive connections with the amygdala, anterior part of cingulate cortex, pre-SMA, portions of the PMV and PPC, ventral striatum, lateral hypothalamus, and periaqueductal gray [17]. Anatomically, dorsal middle insula and SMA [22], inferior frontal gyrus and SMA have direct connection reciprocally by the frontal aslant tract [23]. In clinical studies, analysis of functional coupling during clonic activities in SEEG in two patients with tonic posturing revealed that the middle and posterior insula were more strongly connected to SMA/pre-SMA, while the patient with hypermotor behaviors showed significant functional coupling between the ASG and anterior mesial frontal areas [9]. A cortico-cortical evoked potential study of human insula provided direct evidence supporting that the PSG of both sides had strong connectivity to the frontal operculum and the mesial superior frontal gyrus [24]. Indeed, a combination of hypermotor and tonic/dystonic signs has been

observed in patients with the anterior insular seizure onset zone including the anterior bank of the central insular sulcus, while the dorsal insula tends to be associated with the generation of motor symptoms [7].

Parietal operculum also has early involvement in the network of BATS generation in our group. According to the cerebral cytoarchitecture and connections [25], pure parietal opercular seizures could hardly manifest with BATS. Consistently, in a recent study of Wang et al. [26], there were six patients with pure parietal opercular seizure onset zone; three of them manifested with focal tonic seizures and the other three with hypermotor seizures. No BATS was observed even in the four patients in whom the insula was involved in the propagation network. On the other hand, however, a recent report has described a case of SMA seizure with the seizure onset zone in the secondary leg area on the superior bank of the sylvian fissure, which spread early to the insula. Intensive MRI confirmed the localization of the lesion in the right inferior parietal lobe. The author hypothesized that the insula has a “relay” or “node” function in the parieto-opercular-fronto-medial epileptic network [27]. In most cases, clinical-anatomic analysis of seizure is mainly based on intracranial electrophysiological data, which may cause underestimation of the lesion boundary. Meanwhile, the locations and patterns of ictal discharges have been proven to have certain pathological relations, especially with FCD type II [15]. In this sense, the early spread network would be a specific hint to make the margin of pathological lesions visible, independent of the inherent anatomical functional network. In this study, MRI lesions in three patients (No.5–7) extended from insula to opercular cortex, including parietal operculum, and consistently the ictal discharges started from insula and propagated to parietal operculum and other structures. However, more studies are needed to test the hypothesis that the early spread network of seizure depends not only on anatomical functional network but also on the pathological lesions in insulo-opercular epilepsy.

Limitations

This study has several limitations. This is a retrospective study with a small number of cases. In addition, not all patients were completely seizure-free after surgery. The SEEG electrode sampling did not cover the opercular cortex or the insular gyri completely, which hinders precise localization but allows analyzing the clinical anatomical relationship of ictal BATS network. In addition, we did not compare semiology among different origins within the insulo-opercular region, neither did we distinguish different epileptic networks involved.

Conclusion

In this study, we demonstrated the semiology of SEEG-confirmed insulo-opercular epilepsy with BATS, which

may aid in noninvasive localization and diagnosis. Furthermore, the differences in seizure symptom between insulo-opercular onset and SMA onset may contribute to more accurate localization of epileptogenic areas.

Abbreviations

BATS: Bilateral asymmetric tonic seizure; SEEG: Stereo-electroencephalography; VEEG: Video-electroencephalography; SMA: Supplementary sensorimotor area; pre-SMA: pre-supplementary sensorimotor area; ALG: Anterior long gyrus; PLG: Posterior long gyrus; ASG: Anterior short gyrus; MSG: Middle short gyrus; PSG: Posterior short gyrus; MCC: Middle part of cingulate cortex; PPC: Posterior parietal cortex; PMV: Ventral premotor cortex; TCS: Tonic-clonic seizure; GTCS: Generalized tonic clonic seizure; LVFA: Low voltage fast activity; ALS: Anterior limiting sulcus

Acknowledgements

My deepest gratitude goes first and foremost to Professor Sinclair Liu, who led me into the world of epilepsy semiology and localization. My great thanks would then go to my friend Nan Liu for her help to polish the language. At last, I owe my beloved sister Xiangyu Hu to help improve my writing skills.

Authors' contributions

Design of the work: Xiangshu Hu. Primary data collection and follow-up: Xiaobo Wang, Fang Zeng, Hua Li. Analysis, or data interpretation: Xiao Wang, Qinghua Tan, Ping Yang, Danfang Li, Yang Jin, Lingxia Fei. Drafting the work: Kaihui Li, Junxi Chen. Final approval of the version published and agreement to be accountable for all aspects of the work: Qiang Guo, Xiangshu Hu. The author(s) read and approved the final manuscript.

Funding

Supported by Medical Scientific Research Foundation of Guangdong Province, China (A2020067).

Availability of data and materials

Under request.

Ethics approval and consent to participate

This is a retrospective clinical study. All of the clinical data we used in the paper were from inpatients in Guangdong Sanjiu Brain Hospital. This study was approved by Guangdong Sanjiu Brain Hospital Ethics Committee.

Consent for publication

Yes

Competing interests

No

Author details

¹Epilepsy Center, Guangdong Sanjiu Brain Hospital, No 578, Shatai South Road, Baiyun District, Guangzhou 510510, Guangdong, China. ²Institute for Brain Research and Rehabilitation, South China Normal University, Guangzhou 510631, China.

Received: 7 April 2020 Accepted: 25 September 2020

Published online: 10 November 2020

References

- Commission on Classification and Terminology of the International League Against Epilepsy. Proposal for revised classification of epilepsies and epileptic syndromes. *Epilepsia*. 1989;30:389–99.
- Cai GL, Wang J, Mei X, Zhang W, Luan GM, Liu XZ, et al. Electroclinical semiology of the bilateral asymmetric tonic seizures observed inpatients with supplementary sensorimotor area epilepsy confirmed by pre- and post-operative MRI. *J X-Ray Sci Technol*. 2017;25:247–59.
- Enatsu R, Bulacio J, Nair DR, Bingaman W, Najm I, Gonzalez-Martinez J. Posterior cingulate epilepsy: clinical and neurophysiological analysis. *J Neurol Neurosurg Psychiatry*. 2014;85:44–50.
- Ikeda A, Matsumoto R, Ohara S, Kunieda T, Shirakashi Y, Shibasaki H, et al. Asymmetric tonic seizures with bilateral parietal lesions resembling frontal lobe epilepsy. *Epileptic Disord*. 2001;3:17–22.
- Sitthinamsuwan B, Usui N, Tottori T, Terada K, Kondo A, Inoue Y, et al. Seizures with tonic posturing: Semiologic difference between supplementary sensorimotor area (SSMA) origin and extra-SSMA origin. *Epilepsia*. 2016;57:e39–44.
- Jobst BC, Gonzalez-Martinez J, Isnard J, Kahane P, Lacuey N, Lado F, et al. The insula and its epilepsies. *Epilepsy Curr*. 2019;19:11–21.
- Peltola ME, Trébuchon A, Lagarde S, Scavarda D, Carron R, Bartolomei F, et al. Anatomoelectroclinical features of SEEG-confirmed pure insular-onset epilepsy. *Epilepsy Behav*. 2020;105:106964.
- Wang X, Hu W, McGonigal A, Zhang C, Sang L, Zhang K, et al. Electroclinical features of insulo-opercular epilepsy: an SEEG and PET study. *Ann Clin Transl Neurol*. 2019;6:1165–77.
- Hagiwara K, Jung J, Bouet R, Abdallah C, Guenet M, Isnard J, et al. How can we explain the frontal presentation of insular lobe epilepsy? The impact of non-linear analysis of insular seizures. *Clin Neurophysiol*. 2017;128:780–91.
- Wong CH, Mohamed A, Larcos G, McCredie R, Somerville E, Bleasel A. Brain activation patterns of versive, hypermotor, and bilateral asymmetric tonic seizures. *Epilepsia*. 2010;51:2131–9.
- Bonini F, McGonigal A, Trébuchon A, Gavaret M, Bartolomei F, Chauvel P, et al. Frontal lobe seizures: from clinical semiology to localization. *Epilepsia*. 2014;55:264–77.
- Wen HT, Rhoton AL, de Oliveira E, Castro LH, Figueiredo EG, Teixeira MJ. Microsurgical anatomy of the temporal lobe: part 2—sylvian fissure region and its clinical application. *Neurosurgery*. 2009;65(Suppl 6):1–35 discussion 36.
- Mai JK, Milan M, editors. Human brain in standard MNI space. London: Academic; 2017. p. 36–40.
- Zhang W, Long QT, Guo Q, Liu XZ. Ictal eye movement in posterior epileptic seizure. *J Epilepsy*. 2016;2:406–13.
- Di Giacomo R, Uribe-San-Martin R, Mai R, Francione S, Nobili L, Tassi L, et al. Stereo-EEG ictal/interictal patterns and underlying pathologies. *Seizure*. 2019;27:54–60.
- Sala-Padro J, Fong M, Rahman Z, Bartley M, Gill D, Wong C, et al. A study of perfusion changes with insula epilepsy using SPECT. *Seizure*. 2019;69:44–50.
- Benarroch EE. Insular cortex: functional complexity and clinical correlations. *Neurology*. 2019;93:932–8.
- Catenoix H, Isnard J, Guénot M, Petit J, Remy C, Mauguière F, et al. The role of the anterior insular cortex in ictal vomiting: a stereotactic electroencephalography study. *Epilepsy Behav*. 2008;13:560–3.
- Tarnutzer AA, Mothersill I, Imbach LL. Ictal nausea and vomiting - is it left or right? *Seizure*. 2018;61:83–8.
- Napadow V, Sheehan JD, Kim J, Lacount LT, Park K, Kuo B, et al. The brain circuitry underlying the temporal evolution of nausea in humans. *Cereb Cortex*. 2013;23:806–13.
- Mazzola L, Mauguière F, Isnard J. Electrical stimulations of the human insula: their contribution to the ictal semiology of insular seizures. *J Clin Neurophysiol*. 2017;34:307–14.
- Baker CM, Burks JD, Briggs RG, Conner AK, Glenn CA, Sughrue ME, et al. A Connectomic atlas of the human cerebrum—chapter 5: the insula and Opercular cortex. *Oper Neurosurg (Hagerstown)*. 2018;15(suppl 1):175–244.
- Szmuda T, Rogowska M, Sloniewski P, Abuhaimed A, Szmuda M, Przewozny T, et al. Frontal aslant tract projections to the inferior frontal gyrus. *Folia Morphol (Warsz)*. 2017;76:574–81.
- Dionisio S, Mayoglou L, Cho SM, Prime D, Flanigan PM, Nair D, et al. Connectivity of the human insula: a cortico-cortical evoked potential (CCEP) study. *Cortex*. 2019;120:419–42.
- Pandya DN, Seltzer B, Petrides M, Cipolloni PB, editors. *Cerebral Cortex: Architecture, connections, and the dual origin concept*. New York: Oxford university press; 2015. p. 99–140.
- Wang H, David O, Zhou W, Wang L, Zhang B, Wang Q, et al. Distinctive epileptogenic networks for parietal operculum seizures. *Epilepsy Behav*. 2019;91:59–67.
- Balogh A, Anwar A, Kelemen A, Eröss L, Fabó D. The role of the insula in the parieto-frontomedial epileptic network. Clues from successful surgical treatment. *Ideggyogy Sz*. 2017;70:203–8.